



PATIENT

Apollo Jones

SPECIES

Canine

BREED

Pitbull

SEX

Male

AGE

5 mo

WEIGHT

37.4lbs

INTERPRETED BY

Maggie Machen Lamy,
DVM, DACVIM
(Cardiology)

IMAGING PERFORMED BY

Amanda Lacey-Crook
SDEP-Sonographer

HOSPITAL NAME

River's Edge Pet
Medical Center

REFERRING VET

Dr. Gibson

INVOICE

23535

DATE

4/8/22

PRESENTING CLINICAL SIGNS

History: Pet doing well at home with no concerns. Pet diagnosed with 4-5/6 bilateral systolic heart murmur roughly 3 weeks ago at annual exam and vaccines. Pet very happy and excited today. 4/6 left basilar systolic and 3/6 right basilar systolic heart murmur present with synchronous femoral pulses. Abnormal PE/Chem/CBC/UA Results: ECG report (Idexx): NSR, RAD Sedated with butorphanol.

ECHOCARDIOGRAM FINDINGS

2D, m-mode, color flow and doppler imaging is available. Normal mitral valve leaflets with no obvious prolapse into the left atrial lumen. No obvious mitral regurgitation. Normal left atrial dimension. Normal LV diameter with normal myocardial function. The LV wall appears normal. The tricuspid valve appears mildly elongated with mild insufficiency seen. Moderate right atrial dilation. Significant right ventricular hypertrophy and remodeling indicative of pressure overload. Right ventricular dilation. Pulmonic outflow velocities are elevated at the level of the valve. The pulmonic valve is difficult to visualize extensively. There is significant post-stenotic dilation of the main pulmonary artery and branches. Moderate pulmonic insufficiency. The aortic valve appears to have normal morphology and mobility. Normal outflow velocities. No obvious cardiac shunts are present. No pericardial or pleural effusion noted. Concern for early hepatic congestion.

CARDIAC CHART

CANINE CARDIAC PARAMETERS	MR VMAX (m/s)	TR VMAX (m/s)	LA/AO (Boon method)	LA/AO (Heart Base; Swe)	FS (%)	EF (%)	EPSS (cm)
NORMAL PARAMETER	4.5-5.5	<2.7	1.3	<1.6	28-40	40-100	<0.6
PATIENT	NA	NA	1.3		35	65	0.23
CANINE CARDIAC PARAMETERS	HR (BPM)	AV VMAX (m/s)	PV MAX (m/s)	BODY WEIGHT (kg)	LA 2D short axis Base view (cm)	LVIDd Avg; 2D and m-mode short axis (cm)	LVIDs Avg; 2D and m-mode short axis (cm)
NORMAL PARAMETER	50-100	0.7-1.7	0.7-1.6	BELOW	BELOW	BELOW	BELOW
PATIENT		0.9	5.3	1007		2.9	1.9
*Normal chamber parameters expressed as a mean value (SD)				3	1.27 (5.3)	2.46 (2.46)	1.36 (5.5)
BODY WEIGHT DEPENDENT PARAMETERS				5	1.40 (4.5)	2.74 (5.2)	1.60 (4.7)
<i>*Note: All measurements based upon multi-modal images and methods. An average value is reported.</i>				10	1.50 (3.8)	3.27 (3.5)	2.06 (3.1)
				15	1.83 (2.0)	3.71 (2.4)	2.43 (2.1)
				20	2.02 (1.9)	4.14 (2.2)	2.80 (2.0)
				25	2.18 (2.4)	4.48 (2.9)	3.10 (2.5)
				30	2.33 (3.3)	4.83 (3.9)	3.39 (3.4)
				35	2.48 (4.3)	5.17 (5.0)	3.69 (4.5)
				40	2.62 (5.2)	5.48 (6.1)	3.96 (5.4)
				50	2.88 (7.1)	6.07 (8.3)	4.46 (7.4)

INTERPRETATION OF THE FINDINGS & FURTHER RECOMMENDATIONS

The cause of the murmur is severe pulmonic stenosis. The degree of obstruction is severe based upon the velocity/pressure gradient across the pulmonic valve and the secondary hypertrophy and remodeling of the right ventricle. There is significant RA dilation and mild TR with mild tricuspid valve thickening (likely dysplasia). The risk for CHF in the future is elevated, and will



PATIENT

Apollo Jones

likely limit lifespan. It is particularly concerning that the liver shows signs of early congestion. No other congenital abnormalities were visualized, however small shunts or defects can be difficult to identify without a sedated bubble study and/or advanced imaging.

SPECIES

Canine

Referral for advanced imaging and evaluation for balloon valvuloplasty should be considered in this patient as the gold standard therapeutic option for this condition, and may improve long term outcome and delay onset of clinical signs (including exertional syncope and right-sided congestive heart failure). If surgery is not elected, this patient's condition will likely limit lifespan, with many severe PS cases developing CHF by mid-life. Regardless, medical management with atenolol is recommended to decrease heart rate and lessen the obstruction as below. The patient is bradycardic during the study, likely due to sedation. Reassess baseline HR when sedation is worn off to adjust HR accordingly. Monitor for development of associated clinical signs (collapse, abdominal distention, cough, labored breathing). **Mild exercise restriction is advised.**

BREED

Pitbull

SEX

Male

Breeding this animal is not advised due to the genetic link of this disease.

AGE

5 mo

Anesthetic risk is mild to moderate at this time. **Avoid heart rate stimulating drugs such as atropine or glycopyrrolate unless absolutely necessary.** Avoid vasodilators such as acepromazine. Mild IV fluid restriction is advised. Cardiac protective drug choices (opioid/benzodiazepine premedication, propofol or alfaxalone induction, isoflurane gas) are recommended. Pre-oxygenate for 5-10 minutes prior to induction and recover in O₂ if possible. Monitor for arrhythmias, hypotension, and hypoxia both intra and post-operatively and intervene as necessary.

WEIGHT

37.4lbs

Plan: Institute atenolol to effect: 25mg tabs, ½ tab PO SID to start (up-titrate to desired effect). Goal is to suppress heart rate <120-140bpm even with stress/activity. Referral for balloon valvuloplasty ASAP if desired. If referral is declined, consider addition of spironolactone/ACEI due to early hepatic congestion; Spironolactone 1-2mg/kg PO q12h, ACEI 0.5mg/kg PO q12h.

INTERPRETED BY

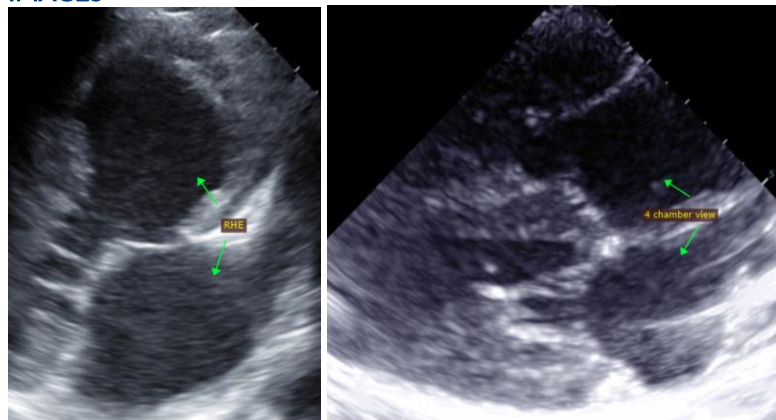
Maggie Machen Lamy,
DVM, DACVIM
(Cardiology)

If surgery is declined, recommend recheck echocardiogram in 6 months to assess for progression, response to medication.

IMAGING PERFORMED BY

Amanda Lacey-Crook
SDEP-Sonographer

IMAGES



HOSPITAL NAME

River's Edge Pet
Medical Center

REFERRING VET

Dr. Gibson

INVOICE

23535

DATE

4/8/22



PATIENT

Apollo Jones

SPECIES

Canine

BREED

Pitbull

SEX

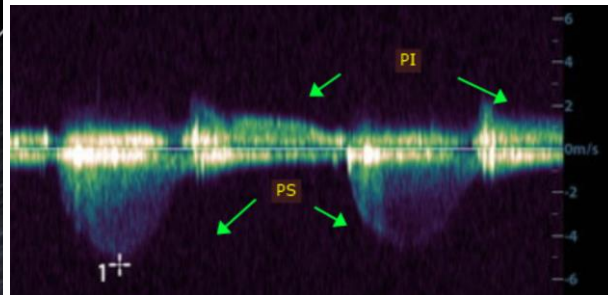
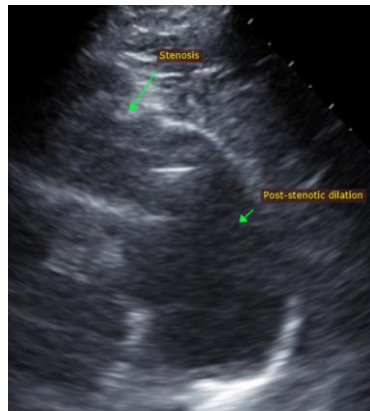
Male

AGE

5 mo

WEIGHT

37.4lbs



The information and recommendations provided are based on the images presented by the referring veterinarian. No evaluation can be communicated regarding pathology that was not visible in the image/video clips provided.

Thank you for this referral. This report was generated using transcription software, and minor dictation errors may be present. If the clinical or image interpretation does not parallel your findings or if I can be of any further assistance please contact me.

Maggie Machen Lamy, DVM
Diplomate of the American College of Veterinary Internal Medicine (Cardiology)
info@sonopath.com

INTERPRETED BY

Maggie Machen Lamy,
DVM, DACVIM
(Cardiology)

IMAGING PERFORMED BY

Amanda Lacey-Crook
SDEP-Sonographer

HOSPITAL NAME

River's Edge Pet
Medical Center

REFERRING VET

Dr. Gibson

INVOICE

23535

DATE

4/8/22